

Meltem Sezis Demirci^{1*}, Cenk Gokalp¹,
Cenk Demirci¹, Emrah Gunay¹, Ayhan
Donmez², Sait Sen³ and Mehmet
Ozkahya¹

¹Ege University Hospital, Nephrology Department,
Izmir, Turkey

²Ege University Hospital, Hematology Department,
Izmir, Turkey

³Ege University Hospital, Pathology Department,
Izmir, Turkey

Dates: Received: 13 June, 2016; Accepted: 11
August, 2016; Published: 13 August, 2016

***Corresponding author:** Meltem Sezis Demirci, Ege
University Hospital, Nephrology Department, Izmir,
Turkey, E-mail: meltem.sezis@ege.edu.tr

www.peertechz.com

ISSN: 2455-5495

Keywords: Membranoproliferative glomerulonephritis;
Non-Hodgkin lymphoma; Nephrotic syndrome

Case Report

Membranoproliferative Glomerulonephritis Preceding Non- Hodgkin Lymphoma Recurrence: A Case Report

Abstract

Introduction: Membranoproliferative glomerulonephritis has been reported to occur in association with non-Hodgkin's lymphoma but there is few information about glomerulonephritis response to the treatment of non-Hodgkin's lymphoma.

Case Presentation: A 67 years-old caucasian female admitted to outpatient clinic with peripheral edema complaint. She had mild proteinuria and microhematuria on admission and tuberculosis, non-Hodgkin lymphoma (cured), diabetes mellitus and hypertension history. Her renal biopsy resulted as membranoproliferative glomerulonephritis and after investigations she got recurrent non-Hodgkin lymphoma diagnosis. After successful treatment of her lymphoma her nephrotic syndrome clinic regressed.

Conclusion: Membranoproliferative glomerulonephritis has been known to be associated with non-Hodgkin's lymphoma. There is limited information available concerning the effects of treatment of non-Hodgkin's lymphoma on the progression of non-Hodgkin's lymphoma associated membranoproliferative glomerulonephritis. We report a rare case of non-Hodgkin's lymphoma associated membranoproliferative glomerulonephritis, that continued to be in remission after chemotherapy treatment of lymphoma.

Background

Membranoproliferative GN (MPGN) accounts for approximately 7%–10% of biopsy-confirmed GN [1]. Clinical presentation varies between mild hematuria/proteinuria and nephrotic syndrome. MPGN can be associated with infections, autoimmune diseases and paraproteinemias [2]. MPGN has been associated with Non-Hodgkin's lymphoma [3], besides there is a few information concerning the effects of treatment of NHL on the clinically associated MPGN.

This report describes a patient who was diagnosed with non-Hodgkin lymphoma after presentation with nephrotic syndrome. Nephrotic syndrome findings of the patient regressed after treatment of lymphoma with chemotherapy.

Case Presentation

A 67 years-old caucasian female patient admitted to hospital with lower extremity edema and dyspnea. She had 2(+) pitting edema on bilateral legs, her chest examination revealed bilateral basal crackles. She had tuberculosis (diagnosed and treated at 1979 and 2012), non-Hodgkin lymphoma (diagnosed at 2006, treated with 6 cycles of chemotherapy), diabetes mellitus (for 25 years) and hypertension (for 6 months) history. She had 4.9 gr/day proteinuria, microscopic hematuria and hypoalbuminemia with normal creatinine value at admission. Her ANA and ANCA results were negative, Erythrocyte Sedimentation Rate (ESR) was 81, CRP: 1,51 mg/dL, C3: 86, C4: <4, Cryoglobulin resulted as 2(+). Renal biopsy was performed and resulted as membranoproliferative glomerulonephritis with

positive C1Q, C3C, IgM, IgA, Kappa immunofluorescein stain. Light microscopic findings of glomerulus showing, endocapillary hypercellularity, and double contours. H&E staining (magnification, × 400) Light microscopic findings of glomerulus showing, endocapillary hypercellularity, and double contours. H&E staining (magnification, × 400) (Figure 1). She had been consulted to hematology department and after the evaluation bone marrow aspiration and biopsy was normal but multiple lymphadenopathies at submandibular, supraclavicular, mediastinal, intraperitoneal and paraaortic lymph nodes observed at her whole-body computerized tomography and PET/CT. Besides multiple lymphadenopathies,

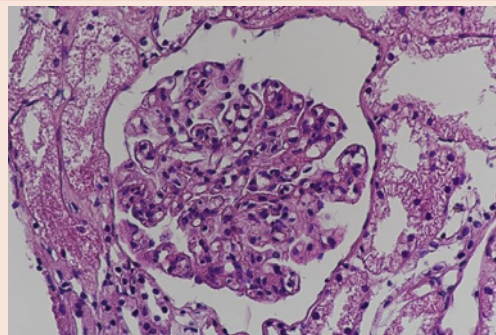


Figure 1: Renal Biopsy – Light microscopic findings of glomerulus showing, endocapillary hypercellularity and double contours, H&E staining (magnification, x400).

ground glass appearance at posterobasal segment of left lower lobe of lung. In order to differentiate any possible infections or malignancy, bronchoscopy was done but cytologic examination was negative for malignant disease. Two weeks of antibiotherapy administered for that consolidation but control PET/CT was showed morphologic and metabolic progression of that consolidated lesion. So another bronchoscopy was done with a tru-cut biopsy and pathology resulted as plasmacytic differentiated MALT lymphoma. After re-evaluation by hematology department patient is considered as relaps lymphoma and she was treated with 6 cycles of CHOP (cyclophosphamide, doxorubicin, vincristine and prednisone) chemotherapy. After 6 cycles of chemotherapy her proteinuria was regressed and her serum albumin level increased to normal level (Table 1). Besides the treatment of lymphoma, her cryoglobulin levels did not change, so glomerulonephritis was secondary to lymphoma not cryoglobulinemia.

Discussion

Glomerular diseases have been known to be associated with both chronic lymphocytic leukemia and non-Hodgkin's lymphoma [4]. MPGN is the most commonly reported histological diagnosis in these diseases. Autoimmune mechanisms, T-lymphocyte dysfunction, production of cryoglobulins and paraproteinemia some of the factors that play role in the pathogenesis of non-Hodgkin's lymphoma-associated glomerulonephritis [5,6]. Chronic hepatitis

C virus infection is currently the most common cause of secondary MPGN and is often associated with cryoglobulinemia. Although HCV serology was negative in this patient, any condition associated with persistent immunological stimulation can result in secondary cryoglobulinemia. Cryoglobulins were positive in our patient at the time of the diagnosis of MPGN and was positive again after the resolution of glomerulonephritis such that cryoglobulinemia can be excluded as a pathogenic mechanism in this patient. Also paraproteins were not detected in our patient.

There is limited information available concerning the effects of treatment of NHL on the progression of NHL associated MPGN. Alshayeb et al reported one patient whom glomerulonephritis continued to be in remission during eleven years of follow up after initial chemotherapy treatment of lymphoma. Moulin, et al. reported one patient with NHL who developed complete remission of MPGN after treatment with chlorambucil and a second patient who showed significantly improved renal function after treatment with MOPP (nitrogen mustard, vincristine, procarbazine, prednisone). Stokes, et al. described a patient with low-grade B-cell lymphoma and MPGN, who responded by improvement in renal function and diminished proteinuria after treatment with oral prednisone.

Conclusion

Secondary membranoproliferative glomerulonephritis can be observed in non-Hodgkin lymphoma patients but there are few reports about clinical results of lymphoma treatment. As we observed clinical remission by successful treatment of lymphoma it should be kept in mind that glomerulonephritis patients, whatever the type is, should be investigated for possible secondary causes.

Consent

The patient that we represent has given her informed consent for the publication of this case report.

Reference

- Masani N, Jhaveri KD, Fishbane S (2014) Update on membranoproliferative GN. *Clin J Am Soc Nephrol* 9: 600-608.
- Renneke HG (1995) Secondary membranoproliferative glomerulonephritis. *Kidney Int* 47: 643-656.
- Dabbs DJ, Morel-Maroger L, Mignon F, Striker G (1986) Glomerular lesions in lymphomas and leukemias. *Am J Med* 80: 63-70.
- Moulin B, Ronco PM, Mougnot B, Francois A, Fillastre JP, et al. (1992) Glomerulonephritis in chronic lymphocytic leukemia and related B-cell lymphomas. *Kidney Int* 42: 127-135.
- Rosas SE, Tomaszewski JE, Feldman HI, Foster MH (1999) Membranoproliferative glomerulonephritis type 1, mixed cryoglobulinemia and lymphoma in the absence of hepatitis C infection. *Am J Nephrol* 19: 599-604.
- Nasr SH, Markowitz GS, Stokes MB, Seshan SV, Valderrama E, et al. (2004) Proliferative glomerulonephritis with monoclonal IgG deposits: a distinct entity mimicking immune-complex glomerulonephritis. *Kidney Int* 65: 85-96.

Table 1: Biochemical result of the patient at pre-chemotherapy and post-chemotherapy period.

	Pre-Treatment	Post-Treatment
AST (U/L)	20	21
ALT (U/L)	13	15
Protein (g/dL)	4.9	6.4
Albumin (g/dL)	3.0	4.2
Ure (mg/dL)	50	47
Creatinine (mg/dL)	0.99	0.66
C3 (mg/dL) (90-180)	86	96
C4 (mg/dL) (10-40)	4	4
ESR (mm/h)	81	
CRP (mg/dL) (0-0.5)	1.51	0.6
Cryoglobulin	2 (+)	2 (+)
ANA	(-)	(-)
ANCA	(-)	(-)
Proteinuria (g/dL)	4.86	0.28
Hematuria (erythrocyte number/hpf)	28	3
HBsAg	(-)	
Anti-HBs IgG (mIU/mL)	(-)	
Anti-HCV	(-)	

Copyright: © 2016 Demirci MS, et al. This is an open-access article distributed under the terms of the Creative Commons Attribution License, which permits unrestricted use, distribution, and reproduction in any medium, provided the original author and source are credited.

Citation: Demirci MS, Gokalp C, Demirci C, Gunay E, Donmez A, et al. (2016) Membranoproliferative Glomerulonephritis Preceding Non-Hodgkin Lymphoma Recurrence: A Case Report. *Arch Renal Dis Manag* 2(1): 024-025. DOI: 10.17352/2455-5495.000012