



Hakam Rabi¹, Emad Qirresh² and Tarek Rabi^{1*}

¹M.Sc. Lecturer, Al-Quds University, Palestine, Jerusalem

²Assistant Professor, Al Quds University Palestine, Jerusalem

Dates: Received: 14 November, 2016; Accepted: 27 February, 2017; Published: 01 March, 2017

***Corresponding author:** Tarek Rabi, M.Sc., Lecturer, Al-Quds University, Palestine, Jerusalem, E-mail: tarekrabi@gmail.com

<https://www.peertechz.com>

Research Article

Radiographic Prescription Trends among Palestinian Dentists for Dental Implant Placement – A Cross Sectional Survey

Abstract

Background: In this present era implant dentistry has seen exponential growth and its success mainly depends upon a proper treatment planning and its execution. Radiographic imaging has a pivotal role in the planning of implant placement and follow up of implant survival.

The Context and Purpose of the Study: To study the radiographic prescription trends for dental implants among Palestinian dental practitioners. A sample of 150 dentists chosen at random in a dental conference received a questionnaire.

Results: 114 dentists returned full questionnaires. It was observed that the majority of the surveyed dentists prescribe panoramic radiographs for dental implant assessment based on its availability. The motivating factors for prescribing the specific radiologic examination was Availability (42.99%), availability + cost(17.53%), Cost + Measurement precision(3.51%), Cost + Radiation Dose(10.53%), Measurement precision(25.44%).

Conclusions: The majority of surveyed dentists prescribe panoramic radiographs for dental implant assessment based on its availability and only a small number strictly adhered to the recommended guidelines of the international associations with regards to cross sectional imaging.

Abbreviations

IOPAR: Intra Oral Periapical Radiograph; OPG: Orthopantomography; CT: Computed Tomography; CBCT: Cone Beam Computed Tomography; AAOMR: American Academy of Oral and Maxillofacial Radiology; EADMFR: European Academy of Dentomaxillofacial Radiology; EAO: European Association for Osseo Integration; ICOI: International Congress of Oral Implantologists; ALARA: As Low As Reasonably Achievable

Introduction

Dental Implants are being widely used for the replacement of missing teeth. Dental practitioners have remarkably taken up this treatment modality and adapted to the advancements in oral rehabilitation. The main criterion in assessing the success of oral implants has been the marginal bone loss evidenced by the radiological examination [1-3]. The imaging objectives aids the clinician in providing the cross-sectional views of the dental arch for visualization of spatial relationship of anatomic

structures of the maxilla and mandible, the quality and quantity of available bone, the presence of infra-bony lesions, the occlusal pattern and the number and size of implants as well as prosthesis design, all which are essential for successful implant treatment planning and evaluation of the ongoing implant functioning [4]. Many types of radiographic modalities are used in implantology namely Intra-Oral Periapical Radiography (IOPAR), Orthopantomography (OPG), occlusal radiography, Conventional tomography, Computed Tomography (CT) and Cone-Beam Computed Tomography (CBCT). Usually, it is up to the practicing clinician to decide which modality best suits their needs [5-7]. The recent position paper on the use of radiology in dental implantology put forward by the AAOMR recommended that cross-sectional imaging be used for the assessment of all dental implant sites and that currently CBCT is the imaging method of choice, at present, to gain this diagnostic information [8]. There is an extreme scarcity worldwide regarding the literature stating the radiographic prescription trends among the implant practitioners worldwide and whether they adhere to the recommendations put forward

by professional bodies like AAOMR, EADMFR, EAO and ICOI [9]. Hence looking at the need of the hour, an attempt was made to survey the radiographic prescription trends among the dental practitioners.

Materials and Methods

150 close ended questionnaires were distributed to the dentists who participated in a dental conference in Ramallah Palestine, in 2015. Out of 150 participants, 114 dentists (65 males, 49 Female) completed the survey. The questionnaire was formatted in a way to enquire about their radiographic prescription methods for pre and post-operative assessment in their implantology practice and data collected regarding the radiographic prescription practices for pre- operative implant assessment and follow up, such as Panoramic Radiograph (OPG), Intra oral Periapical radiograph (IOPAR) and Computed Tomography (CT). The study received ethical approval under the file 9/REC/18. They were also asked whether combination modalities were used in the assessment. The questionnaire also enquired on motivating factors for choosing the radiographic examination, whether they have problems with over or underestimated measurement in panoramic X ray and its frequency, usage of CT for implant imaging and its frequency and the usage of Periapical radiographs. The data collected from the survey were analyzed using Graph Pad Prism software and the results were determined.

Results

The survey was carried out on 114 dentists having clinical experience of more than 10 years (16.67 %), 6-10 years (79.82 %) and 1-5 years (3.51 %). The Gender distribution of radiographic examinations more often prescribed for dental implant assessment were shown in Figure 1. Approximately 59% of dentists prescribe panoramic x-ray whereas 41% of the dentists prescribe a combination of Panoramic X ray + CT imaging.

The motivating factors for prescribing the specific radiologic examination was Availability (42.99%), Availability + Cost (17.53%), Cost + Measurement precision (3.51%) Cost + Radiation Dose (10.53%), Measurement precision (25.44%), Figure 2. Tables 1,2, depict the percent population having problems in measuring panoramic X ray (OPG) and its frequency respectively. It was observed that 34 % of the dentists recommend CBCT Figure 3, with overall medium frequency of 76%, low 3% and minimal 0%. The usage of periapical radiography and the reason for its usage has been shown in Figure 4.

Discussion

The main objective to survey the current radiographic prescription in dental implant assessment was in order to determine the prescription pattern among the experienced dentists and whether dentists are using imaging modalities for implant placement as recommended by the AAOMR. Many options are available, from which the dentist can choose from. However, the choice of radiography is determined by the

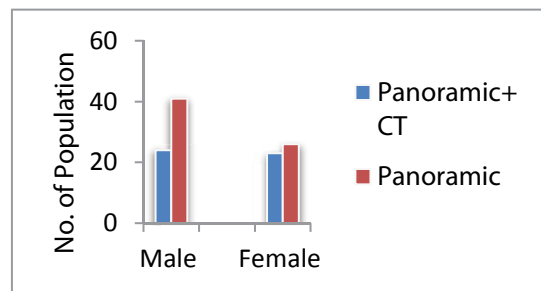


Figure 1: Bar Graph Showing the Gender wise distribution of radiographic examinations more often prescribed for dental implant assessment.

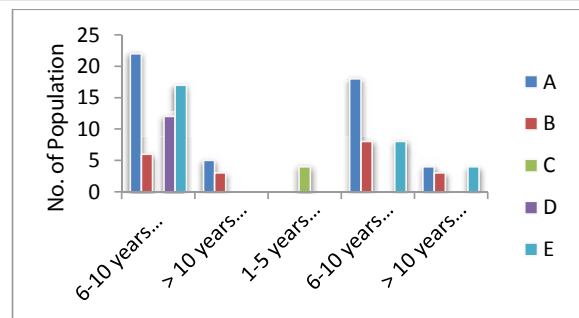


Figure 2: Bar Graph showing Gender & Experience wise distribution of motivating factors for prescribing the specific radiologic examination. A: Availability, B: Availability + Cost, C: Cost + Measurement precision, D: Cost + Radiation dose, E: Measurement precision.

Table 1: Gender and Experience wise table showing problems associated with estimation of Panoramic X ray.

experience	Male				Female			
	overestimation		underestimation		overestimation		underestimation	
	Yes	No	Yes	No	Yes	No	Yes	No
1-5 years					4	0	4	0
6-10 years	34	16	50	0	30	0	30	0
> 10 years	3	4	4	3	9	1	9	1

Table 2: Gender and Experience wise table showing percent frequency of problems in measuring Panoramic X ray.

	Male						Female					
	Overestimation			Underestimation			Overestimation			Underestimation		
	Minimal	medium	low	minimal	medium	low	Minimal	medium	low	Minimal	medium	low
1-5years							0	4	0	0	4	0
6-10 years	34	0	0	34	0	0	30	0	0	30	0	0
>10 Years	0	0	3	0	0	3	9	0	0	9	0	0

advantages and disadvantages of each modality [10,11]. The pattern of radiographic choices and number of years of experience was similar to that observed in a study done by McCrea [12]. In the present study, the panoramic radiograph was the most frequent radiographic examination prescribed for treatment planning of Osseo-integrated implants. Approximately, 59% of dentists prescribed the panoramic radiograph, as a single examination technique and 41% of dentists combined it with a computed Tomography examination. The results of this study was in agreement with those obtained by Beason and Brooks [13], Sakakura, et al. [14], De Morais et al. [15].

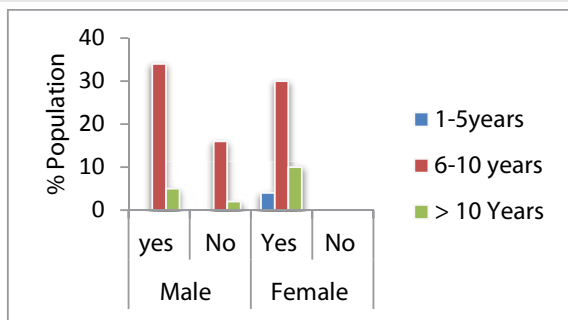


Figure 3: Bar Graph Showing Gender and experience wise % population using Computed Tomography (CT).

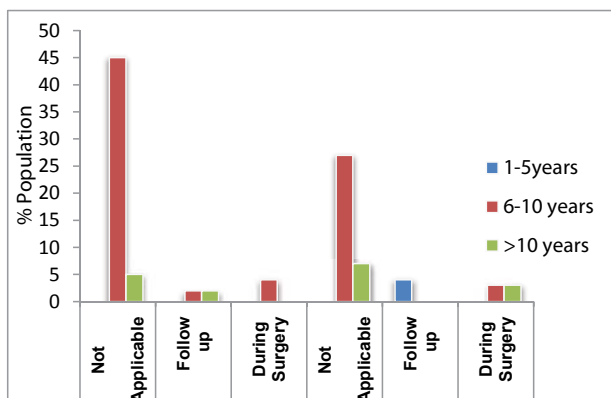


Figure 4: Bar Graph showing Gender and experience wise % Population using Periapical radiograph (IOPAR) and the reason for its usage.

The panoramic radiograph gives useful information in the initial evaluation for pre-operative planning, but owing to its large horizontal magnification varying regionwis. Another limitation is the lack of information in the third dimension [6-8]. An important aspect to be considered in the implant imaging prescription is the radiation dose. However in this study only 11% dentists looked on this reason for prescribing radiologic examination and the most observed reason for choosing the radiologic examination was its availability following by the measurement precision. This results are in consistent with that obtained by Majid et al. [16]. Although panoramic radiograph requires only a small radiation dose, it does not provide information in the third dimension, which is considered necessary by some [17]. Following the ALARA principle, for cross-sectional imaging the AAOMR [8], recommends conventional tomography for one to seven implant sites and CT for eight or more implant sites. The Cone Beam Computed Tomography (CBCT) is one of the more recent trends being used in radiography for implants [18].

When comparing the frequency of over- and underestimated measurements of Panoramic radiography it was found that 50 % of dentists tends to underestimate and 34 % dentist overestimate the measurement. This fact can be explained by the presence of different levels of magnification and distortion related to anatomical regions and lack of cross-sectional images [19,20]. Also, PAN presents a 2-dimensional image with no information about buccal-lingual thickness [1]. The

image magnification and the low reproducibility of alveolar canal diagnosis can increase the risks of anatomical structure damage to the inferior alveolar [13-15].

Our study also interviewed the % dentists using periapical radiographs and its reason. It was found that only a small percentage of dentists uses it during surgery and follow up whereas as majority of them tends to avoid it Peñarrocha M et al. [21], suggested that conventional periapical radiographs and digital radiographs were more accurate than panoramic radiographs in the assessment of peri-implant bone loss. Periapical radiographs requires less radiation dose; produces minimal magnification and a minimally distorted relationship between the bone height and adjacent teeth [8], making it a more convenient diagnostic tool in clinical practice. However it was overlooked by most of the dentists in our study.

Within the limitation of smaller sample size our study tries to emphasize the current radiographic prescription trends in the studied population.

Conclusion

This study has shown that the majority of dentists sampled prescribe panoramic radiographs for dental implant assessment based on its availability and only a small number strictly adhered to recommended guidelines of the world associations with regards to cross sectional imaging.

References

- Adell R, Lekholm U, Rockler B, Brånemark PI (1981) A 15-year study of osseointegrated implants in the treatment of the edentulous jaw. *Int J Oral Surg* 10: 387-416. [Link: https://goo.gl/7FrR67](https://goo.gl/7FrR67)
- Albrektsson T (1988) A multicenter report on osseointegrated oral implants. *J Prosthet Dent* 60: 75-84. [Link: https://goo.gl/NrHgal](https://goo.gl/NrHgal)
- Andersson B, Odman P, Lindvall AM, Brånemark PI (1998) Five-year prospective study of prosthodontic and surgical single-tooth implant treatment in general practices and at a specialist clinic. *Int J Prosthodont* 11: 351-355. [Link: https://goo.gl/sDTFn1](https://goo.gl/sDTFn1)
- Engelman MJ, Sorensen JA, Moy P (1988) Optimum placement of osseointegrated implants. *J Prosthet Dent* 59: 467-473 [Link: https://goo.gl/q1FRPI](https://goo.gl/q1FRPI)
- Stella JP, Tharanon W (1990) A precise radiographic method to determine the location of the inferior alveolar canal in the posterior edentulous mandible: Implications for dental implants. Part 1: Technique. *Int J Oral Maxillo fac Implants* 5: 15-22. [Link: https://goo.gl/XNTmdm](https://goo.gl/XNTmdm)
- Klinge B, Petersson A, Maly P (1989) Location of the mandibular canal: Comparison of macroscopic findings, conventional radiography, and computed tomography. *Int J Oral Maxillo fac Implants* 4: 327-332. [Link: https://goo.gl/ArqDC4](https://goo.gl/ArqDC4)
- Lindh C, Petersson A (1989) Radiologic examination for location of the mandibular canal: A comparison between panoramic radiography and conventional tomography. *Int J Oral Maxillo fac Implants* 4: 249-253. [Link: https://goo.gl/jiKobj](https://goo.gl/jiKobj)
- Tyndall DA, Brooks SL (2000) Selection criteria for dental implant site imaging: A position paper of the American Academy of Oral and Maxillofacial radiology. *Oral Surg Oral Med Oral Pathol Oral Radiol Endod* 89: 630-637. [Link: https://goo.gl/Ptdl2Z](https://goo.gl/Ptdl2Z)

9. Scaf G, Lurie AG, Mosier KM, Kantor ML, Ramsby GR, et al. (1997) Dosimetry and cost of imaging osseointegrated implants with film-based and computed tomography. *Oral Surg Oral Med Oral Pathol Oral Radiol Endod* 83: 41-48. [Link: https://goo.gl/vRCm1d](https://goo.gl/vRCm1d)
10. Monsour PA, Dudhia R (2008) Implant Radiography and Radiology. *Aust Dent J* 53: S11-S25. [Link: https://goo.gl/tEP7gY](https://goo.gl/tEP7gY)
11. Sarik Gupta, Neelkant Patil, Jitender Solanki, Ravinder Singh, Sanjeev Laller (2015) Oral Implant Imaging: A Review. *Malays J Med Sci* 22: 7-17. [Link: https://goo.gl/10m8Jf](https://goo.gl/10m8Jf)
12. SJJ McCrea (2008) Pre-Operative radiographs for dental implants-are selection criteria being followed? *Bri Dent J* 204: 675-682. [Link: https://goo.gl/ZGHB2d](https://goo.gl/ZGHB2d)
13. Beason RC, Brooks SL (2001) Preoperative implant site assessment in southeast Michigan. *J Dent Res* 80: 137. [Link: https://goo.gl/NiVqF3](https://goo.gl/NiVqF3)
14. Sakakura CE, Morais JA, Loffredo LC, Scaf G (2003) A survey of radiographic prescription in dental implant assessment. *Dentomaxillo fac Radiol* 32: 397-400. [Link: https://goo.gl/IXHDBa](https://goo.gl/IXHDBa)
15. deMorais JA, Sakakura CE, LoffredoLde C, Scaf G (2007) A survey of radiographic measurement estimation in assessment of dental implant length. *J Oral Implantol* 33: 186-190. [Link: https://goo.gl/W19Xwg](https://goo.gl/W19Xwg)
16. Majid IA, Mukithur Rahaman S, Kumar H, Sowbhagya MB, Alikutty FK (2014) Radiographic prescription trends in dental implant site. *J Dent Implant* 4: 140-143. [Link: https://goo.gl/EZUDF4](https://goo.gl/EZUDF4)
17. Aishwarya Nagarajan, Rajapriya Perumalsamy, Ramakrishnan Thyagarajan, Ambalavanan Namasivayam (2014) Diagnostic Imaging for Dental Implant Therapy. *J Clin Imaging Sci* 4: 4. [Link: https://goo.gl/Gkl60p](https://goo.gl/Gkl60p)
18. Naseem Shah, Nikhil Bansal, Ajay Logani (2014) Recent Advances in imaging technologies in dentistry. *World J Radiol* 6: 794-807. [Link: https://goo.gl/4i4Ycm](https://goo.gl/4i4Ycm)
19. Reddy MS, Mayfield Donahoo T, Vandervan FJ, Jeffcoat MK (1994) A comparison of the diagnostic advantages of panoramic radiography and computed tomography scanning for placement of root form dental implants. *Clin Oral Implants Res* 5: 229-238. [Link: https://goo.gl/k63G3x](https://goo.gl/k63G3x)
20. Bolin A, Eliasson S, von Beetzen M, Jansson L (1996) Radiographic evaluation of mandibular posterior implant sites: Correlation between panoramic and tomographic determinations. *Clin Oral Implants Res* 7: 354-359. [Link: https://goo.gl/UeD4CY](https://goo.gl/UeD4CY)
21. Peñarrocha M, Palomar M, Sanchis JM, Guarinos J, Balaguer J (2004) Radiologic study of marginal bone loss around 108 dental implants and its relationship to smoking, implant location, and morphology. *Int J Oral Maxillofac Implants* 19: 861-867. [Link: https://goo.gl/hQVRE7](https://goo.gl/hQVRE7)

Copyright: © 2017 Rabi H, et al. This is an open-access article distributed under the terms of the Creative Commons Attribution License, which permits unrestricted use, distribution, and reproduction in any medium, provided the original author and source are credited.