



Romanova Julia¹ and Koval Svitlana^{2*}

¹Department of Therapeutic Dentistry, Odessa National Medical University

²Department of Therapeutic Dentistry, Odessa National Medical University, Private Orthodontic Clinic "SK Dental», Odessa, Ukraine

Dates: Received: 05 June, 2017; **Accepted:** 21 June, 2017; **Published:** 23 June, 2017

***Corresponding author:** Koval Svitlana, MSc, Orthodontist, Department of Therapeutic Dentistry, Odessa National Medical University, Private Orthodontic Clinic SK Dental, Odessa, Ukraine, Tel: +00380677661463; Email: sve.koval@icloud.com

<https://www.peertechz.com>

Research Article

The procedure of Anteroposterior Tooth Contact Adjustment (APTCA) in Orthodontic patients

Abstract

Orthodontic relapse is the major concern in both adolescent and adult orthodontic treatment. The causes of orthodontic relapse are reported to be of various origins. Functional diagnostic procedures allow to report the presence of disturbances in temporomandibular joint functioning, chewing muscle functioning and tooth contacts. The T-scan computerized occlusal analysis is aimed to diagnose the presence of tooth contacts that contribute to the overall imbalance in the occlusal pattern, the presence of force outliers which contribute to excessive teeth load and the timing characteristics of the functioning occlusion. The procedure of Anteroposterior tooth contact adjustment (APTCA) was worked out to analyze the presence of factors contributing to the anterior teeth movements after the completion of orthodontic treatment and subsequently to diminish the risk of the orthodontic relapse caused by these tooth contacts.

Introduction

Orthodontic relapse is the main concern regarding the stability of orthodontic treatment outcome. Various causes were reported in the literature to contribute to orthodontic relapse [1,2]. Different malocclusion types show various prevalence of tendency to relapse [3,4], moreover, different orthodontic treatment techniques can predispose to post treatment tooth movements [5]. Both type of retention appliance and the retention protocol are considered to be the main contributing factors. Both occlusal contacts are targeted during orthodontic relapse examination [6-8] and electromyographic activity of chewing muscles [9].

Occlusal relationships were reported to cause tooth movements after the completion of orthodontic treatment [10,11] as well as signs and symptoms of temporo-mandibular dysfunction [12,13]. T-scan occlusal analysis (Tekskan, USA) was used to analyze occlusal relationships [14] and the distribution of forces during functional jaw movements [8,9,15-18]. Detailed time report can be acquired as well as the duration of tooth contacts in different jaw movements and positions with the use of T-scan occlusal analysis. T-scan computerized occlusal analysis is currently the only procedure which can be used to calculate the amount of relative force and the duration of contacts along the dental arches.

We have developed a T-scan based occlusal analysis

procedure which can be used to reveal contacts which contribute to orthodontic relapse after the completion of treatment.

Computer-guided occlusal adjustment named anteroposterior tooth contact adjustment (APTCA) is an orthodontic alternative to the earlier described technique of Immediate Complete Anterior Guidance Development (ICAGD), first introduced by Kerstein in 1992 [19]. The APTCA technique is aimed to lessen anterior tooth movements caused by contacts on posterior teeth that prolong disclusion time, thus decreasing the risk of orthodontic relapse in the upper anterior region (Figure 1).

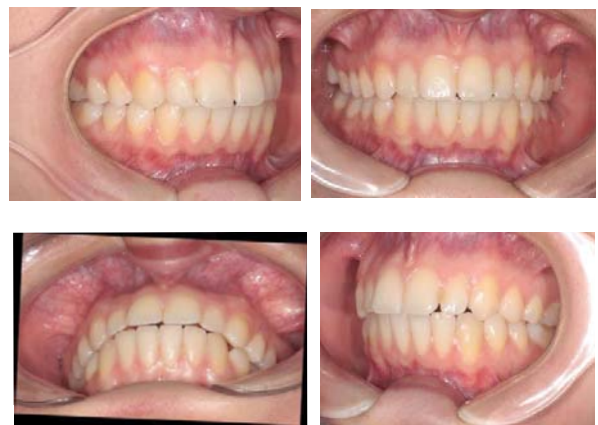

Figure 1: Occlusion after the completion of orthodontic treatment.

Newly established orthodontic occlusion lacks multiple contacts and the remaining contacts are not balanced to perform smooth lateral excursions.

The procedure of the APTCA goes in the following sequence. After debanding patient is examined with T-scan III occlusal analysis procedure. The recording sequence is: centric occlusion, multi-bite, left lateral, and right lateral. Then occlusal foil (8 microns, Arti-Fol, Bausch, Germany) is placed between the teeth, patient is then asked to bite with the articulating paper in the mouth (Figure 2). Operator holds the articulating paper while the patient bites in his centric occlusion. These marks are then compared to the occlusal contacts viewed on the screen in patient's centric occlusion recording (Figure 3). The highest forces on the teeth, which are seen on the screen exceeding the overall force level of 82%, have to be eliminated in the mouth. The force outliers on the screen are compared with paper marks on the patient's teeth. The level of force does not usually correlate with the size of the occlusal mark. As described by Kerstein [20], small paper marks often tend to exhibit higher forces than larger marks.

After having eliminated extremely high forces marked in red and purple in centric occlusion, lateral excursions are analyzed. The purpose of lateral excursion recording is, first, to determine the time of disclusion (DT), and, secondly, to eliminate any contact on posterior maxillary and mandibular molars that prolongs the DT. One of these contacts, as shown in the case reports [10,11], is potentially prone to cause either buccal inclination of anterior teeth, or their rotation.

The APTCA procedure is implemented by disclusion time reduction, which was first described by Kerstein [19,21], in the region on posterior teeth, both maxillary and mandibular. First patient is asked to bite on the sensor in his centric occlusion and then slightly move to canine edge-to-edge contact (Figure 4). The recording is then analyzed and the DT is checked (Figure 5). DT should not exceed 0,5 seconds [20]. Then the patient is asked to occlude his teeth in centric occlusion with green occlusal paper between his teeth. The excursive movement is afterwards performed with the use of red occlusal paper to mark excursive contacts. The method implements two colors of occlusal paper to mark centric occlusal contacts in green and excursive contacts in red. Red marks are easily recognizable and can be removed according to canine guidance scheme. The aim of APTCA is to achieve pure canine guidance in 0,5 seconds, eliminating posterior excursive contacts primarily. These contacts are consequently removed after each recording. The patient performs excursive movement with a sensor,

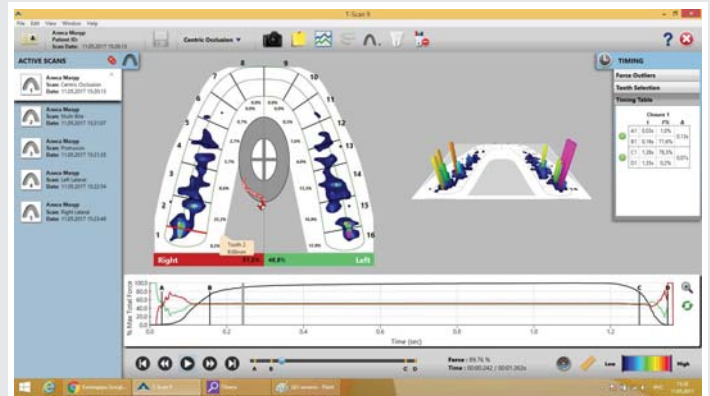


Figure 3: Patient's centric occlusion recording.

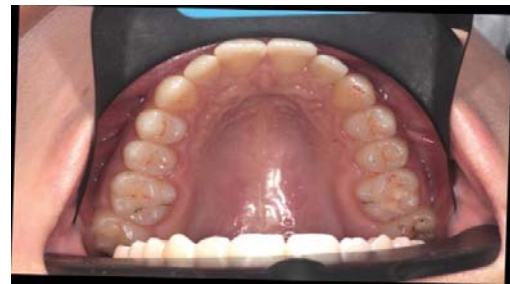

Figure 4: Patient's left lateral excursion marks.

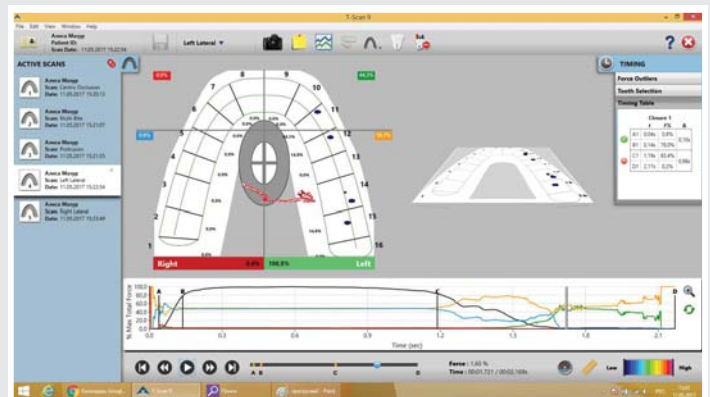


Figure 5: Left lateral excursion.

paper marks are checked in the mouth, then excursive contacts removed on posterior teeth, and again the patient is asked to bite the sensor. It may take up to 8-10 cycles of repeated adjustment to achieve proper DT on the working side. The same procedure is done on the opposite side, when the patient performs lateral movement on the opposite working side.

Great emphasis is put on eliminating working contacts on the teeth posterior to ipsilateral canine. If teeth are already severely worn or sensitivity level is high, or canine is worn itself, canine's restoration is essential to restore proper function and secure post treatment stability.

Excursive movements are performed on each side, both left and right. (Figure 6). Disclusion time is analyzed and compared to the estimated normal time of 0,5 seconds. Any contacts on both working and non-working sides which tend to prolong the disclusion time should be eliminated.

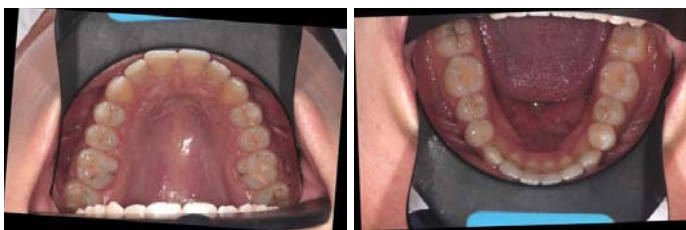

Figure 2: Occlusal marks in Centric occlusion.

Protrusion movement is of a great value as well (Figure 7). The discussion time in protrusive movements is also expected to be not more than 0,5 seconds (Figure 8). Any contacts tending to prolong discussion time in protrusive movement will tend to move the upper anterior teeth in buccal direction. The distribution of posterior contacts causes selective influence on anterior teeth.

Conclusion

Patients` concern about orthodontic stability raises the point of seeking different approaches to finishing orthodontic cases. Both different kinds of orthodontic retainers and settling procedures try to establish optimum and stable results. This chapter introduces the concept of functional corrections by T-scan III occlusal analysis system. The newly developed

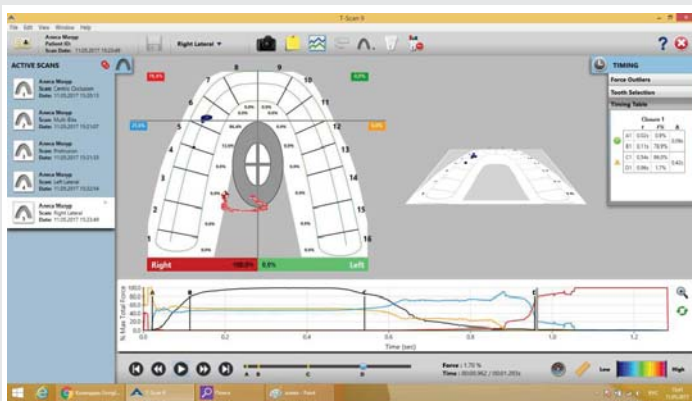

Figure 6: Right lateral movement.

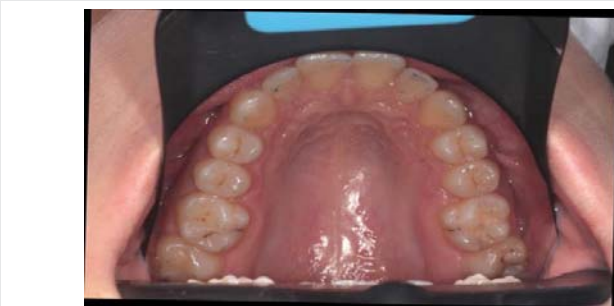

Figure 7: Occlusal contacts in protrusive movement.

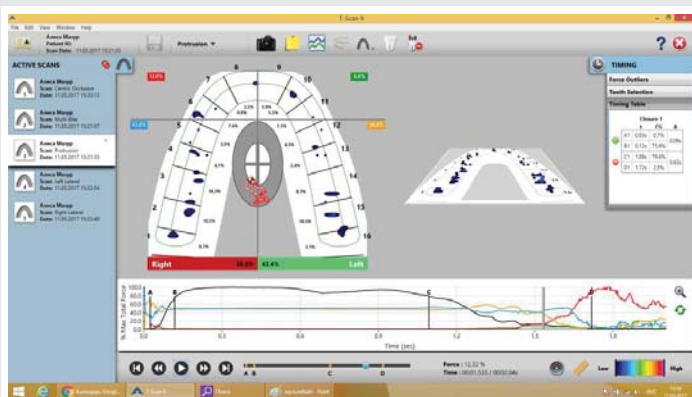


Figure 8: T-scan occlusal recording of protrusive movement.

anteroposterior tooth contact adjustment (APTCA) procedure decreases the risk of orthodontic relapse caused by posterior excursive contacts. The implementation of the APTCA procedure is outlined and the main characteristics of T-scan III software are given. The APTCA procedure is aimed to secure orthodontic treatment stability and eliminate any functional interferences, which may later cause muscle and TMJ dysfunctions.

References

- Lyotard N, Hans M, Nelson S, Valiathan M (2010) Short-term post orthodontic changes in the absence or retention. The Angle Orthodontist 80: 1045-1050. [Link: https://goo.gl/xPSDpH](https://goo.gl/xPSDpH)
- Greco PM, English JD, Briss BS, Jamieson SA, Kastrop MC, et al. (2010) Posttreatment tooth movement: For better or for worse. American Journal of Orthodontics and Dentofacial Orthopedics 13: 552-558. [Link: https://goo.gl/gEhDnu](https://goo.gl/gEhDnu)
- Angle EH (1899) Classification of malocclusion. Dental Cosmos 41: 248-264.
- Andrews LF (1979) The six keys to normal occlusion. American journal of Orthodontics. 62: 296-309. [Link: https://goo.gl/v2E6Qv](https://goo.gl/v2E6Qv)
- McLaughlin R, Bennet J, Travis H (2001) Systemized Orthodontic Treatment Mechanics, 2001. St. Louis, MO: CV Mosby. [Link: https://goo.gl/wbqzVS](https://goo.gl/wbqzVS)
- Ash MM, Nelson SJ (2002) Wheeler's dental anatomy, physiology, and occlusion, ed 8, St Louis, Saunders 29-64. [Link: https://goo.gl/wbqzVS](https://goo.gl/wbqzVS)
- Ricketts RM (1969) Occlusion - the medium of dentistry. The Journal of Prosthetic Dentistry 21: 39-60. [Link: https://goo.gl/rJYxsC](https://goo.gl/rJYxsC)
- Ricketts RM (1978) A detailed consideration of the line of occlusion. The Angle Orthodontist 48: 274-282. [Link: https://goo.gl/czSjFY](https://goo.gl/czSjFY)
- Williams EH, Lundquist DO (1983) Anterior guidance: its effect on the electromyographic activity of the temporal and masseter muscles. J Prosthet Dent 49: 816-823. [Link: https://goo.gl/3fx3gi](https://goo.gl/3fx3gi)
- Koval S (2016) T-scan occlusal analysis after adult orthodontic treatment. J Clin Orthod 50: 466-475. [Link: https://goo.gl/CD0844](https://goo.gl/CD0844)
- Koval S (2016) T-scan III computed guided occlusal adjustment in orthodontic relapse patient. The procedure description. EC Dental Science 6: 1297-1308. [Link: https://goo.gl/1b85oa](https://goo.gl/1b85oa)
- Williamson EH, Simmons MD (1979) Mandibular asymmetry and its relation to pain dysfunction. Am J Orthod 76: 612-617. [Link: https://goo.gl/NBpYhm](https://goo.gl/NBpYhm)
- Brandt D: Temporomandibular disorders and their association with morphologic malocclusion in schoolchildren. In Carlson DS, McNamara JA, Ribbons KA, editors: Developmental aspects of temporomandibular joint disorders, Ann Arbor, 1985, University of Michigan Press, pp 279-283.
- Cohen J, Cohen N (2011) Computerized analysis of occlusal contacts after lingual orthodontic treatment in adults. Int Orthod 9: 410-431. [Link: https://goo.gl/P51Z64](https://goo.gl/P51Z64)
- Qadeer S, Abbas AA, Sarinnaphakorn L, Kerstein RB (2016) Comparison of excursive occlusal force parameters in post-orthodontic and non-orthodontic subjects using T-Scan® III. Cranio. 2016 Nov 23:1-8. [Link: https://goo.gl/BPQhDL](https://goo.gl/BPQhDL)
- Qadeer S, Abbas AA, Sarinnaphakorn L, Kerstein RB (2016) Comparison of closure occlusal force parameters in post-orthodontic and non-orthodontic subjects using T-Scan® III DMD occlusal analysis. Cranio. 34: 395-401. [Link: https://goo.gl/f24TJ5](https://goo.gl/f24TJ5)
- Kerstein RB (2015) Handbook of Research on Computerized Occlusal analysis Technology Applications in Dental Medicine. IGI Global. [Link: https://goo.gl/oHgFze](https://goo.gl/oHgFze)



18. Kerstein RB, Radke J (2016) Average chewing pattern improvements following Disclusion Time reduction. *Cranio* 22:135-151. [Link: https://goo.gl/EV6vAZ](https://goo.gl/EV6vAZ)

19. Kerstein RB (1992) Discussion time reduction therapy with immediate complete anterior guidance development: The technique. *Quintessence International* 735-747. [Link: https://goo.gl/x75PyW](https://goo.gl/x75PyW)

20. Kerstein RB (1994) Discussion time measurement studies, Stability of discussion time. A 1 year follow-up study. *The Journal of Prosthetic Dentistry* 72: 164-168. [Link: https://goo.gl/K2L7Ei](https://goo.gl/K2L7Ei)

21. Kerstein RB (1993) A comparison of traditional occlusal equilibration and immediate complete anterior guidance development. *The Journal of Cranio-Mandibular Practice* 11: 126-140. [Link: https://goo.gl/xWSQUR](https://goo.gl/xWSQUR)

Copyright: © 2017 Romanova J, et al. This is an open-access article distributed under the terms of the Creative Commons Attribution License, which permits unrestricted use, distribution, and reproduction in any medium, provided the original author and source are credited.

Citation: Romanova J, Koval S (2017) The procedure of Anteroposterior Tooth Contact Adjustment (APTCA) in Orthodontic patients. *J Dent Probl Solut* 4(3): 044-047. DOI: <http://doi.org/10.17352/2394-8418.000047>